



OPD ASSESSMENT FORM

Date :-

22/4/26

PATIENT NAME :

Akhatac Ansari

CONSULTANT :

Dr M. N. Parkar

Age :-

69

Sex :-

M

Ht :-

Wt :-

72.5

IBW :-

BMI :-

Appetite : Good / Fair / Poor / Unable to eat


T - 18 F - P - 8 L RR - 20

Food Allergies :

Food Intolerance :

SPu - 96.1

History & Finding :



Gastrointestinal

BP - 120/80

Investigations & Treatment :

$HAH = 12.1$
 $CME TC = 12700$
 $SGOT = 118$
 $RLM = 116$

Name of Drugs (in CAPITALS)	Dosage	Frequency & Quantity				Relationship with Food	
		M	A	N	Others	Before	After
13/11/25 DSG → Multiple (M) (C) (A) (W) (N)							

Signature of the Doctor :

Next Visit :



A-ONE DIAGNOSTIC CENTER

Fully Computerised Pathology

Sample
Collection :

Dr. Lal PathLabs



Thyrocare
Tests you can trust



SRL
Diagnostics



Patient's Name : Mr. AKHTAR

Age : 65

Gender : Male

Referred By : Dr.R.Kumar BHMS

Lab code : 6892

Collection Date : 13-04-2026

Report Date : 13-04-2026



LIVER FUNCTION TEST

Test Name	Results	Unit	Normal Range
S.BILIRUBIN(Total)	0.61	mg/dl.	0.1-1.2
S.BILIRUBIN(Direct)	0.40	mg/dl.	0-0.3
S.BILIRUBIN(Indirect)	0.21	mg/dl.	0.1-1.0
TOTALPROTEINS	6.92	gms/dl.	6.0-8.0
ALBUMIN	3.39	gms/dl.	3.5-5.0
GLOBULIN	3.53	gms/dl.	1.5-3.6
A:GRATIO	0.96		
ALKALINEPHOSPHATASE	80	IU/L	41-141
S.G.O.T.	26.3	IU/ml	UPTO 37
S.G.P.T.	17.7	U/L	UPTO 40

---End of Report---

Technician
Santosh Kumar

Emergency Service 24x7 Available
Not For Medico Legal Purpose Use only For Treatment
Home Blood Collection Sample | Cont. No.: 9852232456
Main Road, Guraru Bazar, Gaya



रात दिन सेवा उपलब्ध

9934614734

आदर्श क्लिनिक

डॉ० राजेश कृ० 'विद्युत'
B.H.M.S. (B.U.)
Physician & Surgeon
Reg. No-32177



Dr. Rajesh Kr. 'Vidyut'
B.H.M.S. (B.U.)
Physician & Surgeon
Reg. No-32177

पता: सूर्य मंदिर से पूरब, गुरारू (गया)

Name :- Akhtar

Age :- 65 Date :- 13.4.2026

Add :- Raudsmath

no constipation

Rx - USG whole Abdomen

- Livacon syp.

10 ml x 2 an

600/1
लगाने

- Diabepsin - syp.

10 ml x 2 an

- Par D - D - (10)

10/1

- Xone1 an. - (6)

Agar - an in.

दवा हमेशा दिखाकर प्रयोग करें।



करण अल्ट्रासाउण्ड

R. N. 103/2018

KARAN ULTRASOUND

नियर बैंक ऑफ बड़ौदा, मथुरापुर रोड, गुरारू (गया जी)



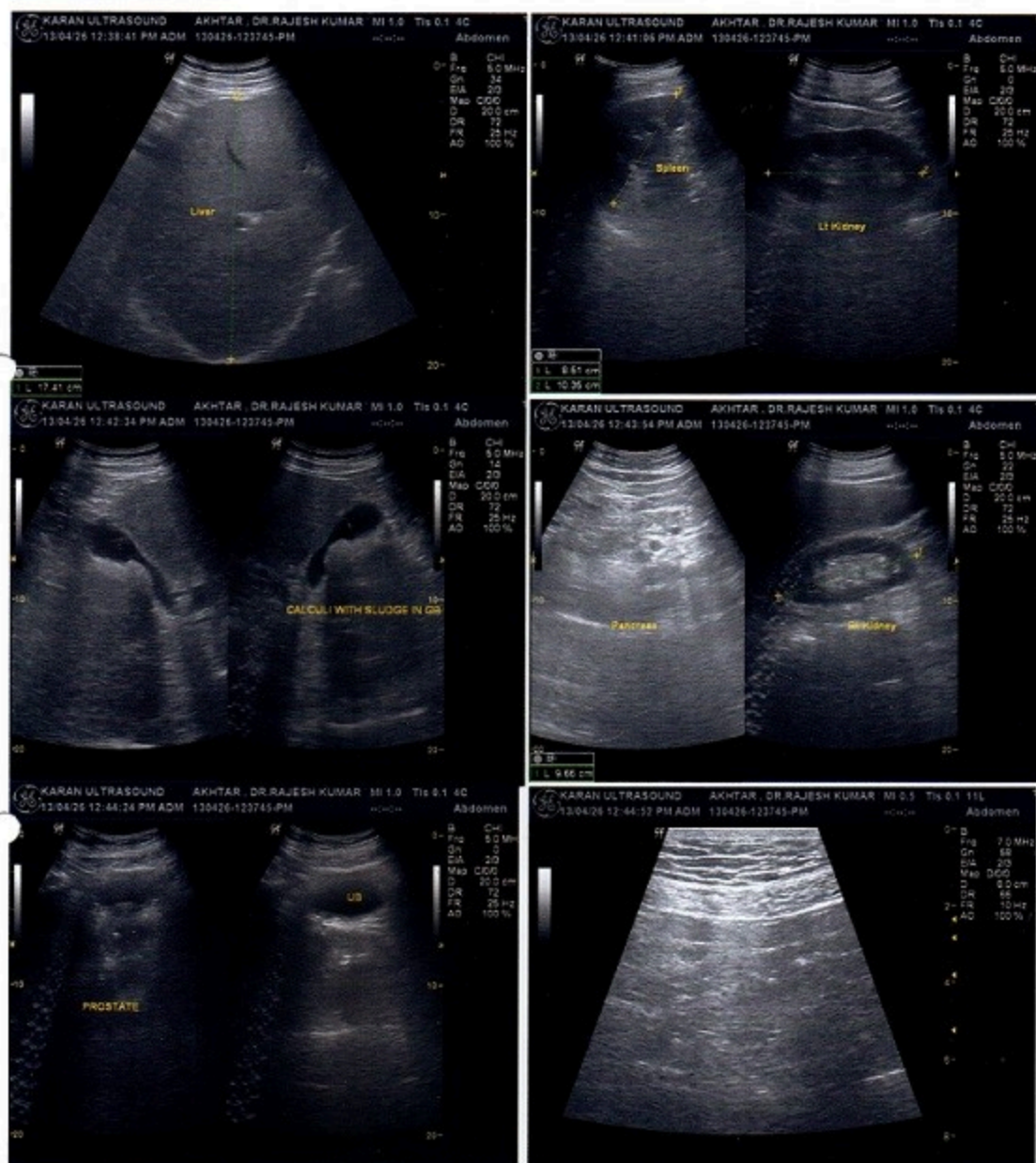
NAME : AKHATAR	AGE : YRS	SEX : MALE
REFD. : DR.RAJESH KUMAR VIDYUT (BHMS)	USG : WHOLE ABDOMEN	DATE : 13/04/2026

THANKS FOR THE KIND REFERRAL.

- LIVER:-** Liver parenchyma is enlarged, measures 174 mm in AP diameter. No focal lesion seen. There is no evidence of dilated intrahepatic ducts.
- C.B.D. -** CBD is normal in caliber measures 3.1 mm. No intraluminal mass or calculi seen.
- G.B.:-** There are multiple calculi seen in gall bladder with echogenic sludge, larger one measures 4.3 mm in diameter. The G.B. Wall measures 1.8 mm in thickness.
- PANCREAS:-** Pancreas is normal in size, outline and echo texture. No pseudo cyst or mass seen. Pancreatic duct is not dilated. No peripancreatic collection seen.
- SPLEEN:-** Spleen is normal in size and echopattern, measures 85 mm in bipolar diameter.
- VESSELS:-** Main Portal vein, Hepatic veins, IVC and abdominal aorta are normal
- KIDNEYS:-** Both kidneys are normal. The right kidney measures 96 mm and the left kidney 103 mm in bipolar diameter. No calcification or hydronephrotic changes seen. The cortico-medullary distinction is intact. Ureters not dilated seen.
- U.BLADDER:-** Urinary bladder is seen normally distended and normal wall thickness. No calculi or mass seen within it.
Pre void bladder volume -- 50 Mls. Post void bladder volume -- insignificant.
- PROSTATE:-** Prostate is normal, measures 18 Gms. Capsule is intact
- OTHERS:-** No lymphadenopathy or ascites. No collection or mass seen in RIF.
- IMPRESSION:-**
HEPATOMEGALY.
MULTIPLE CALCULI IN GALL BLADDER WITH ECHOGENIC SLUDGE.
NO OTHER ABNORMALITY SEEN.
- PLEASE CO-RELATE CLINICALLY.


Dr. Vinod Kumar
M.B.B.S. (Sonologist)

KINDLY CO-RELATE CLINICALLY, NOT FOR MEDICO LEGAL PURPOSE
नोट : अल्ट्रासाउण्ड द्वारा गर्भ में लिंग निर्णय की सुविधा यहाँ उपलब्ध नहीं है।

KARAN ULTRASOUND, GURARU



جامعہ فیضان اعلیٰ حضرت ٹرسٹ

JAMIA FAIZAANE AALA HAZRAT TRUST

Regn. No.: E 6627 (Thane)



Jubli Park, Shri Lanka, Devri Pada, New Kausa, Mumbra, Dist. Thane-400612

Date: 23/04/2026

نام - اختر حسین ابن رمضان میان عمرہ 7 سال
ساکن - رود امروہ، پوسٹ، منیری ضلع تبا بہار۔

مذکورہ شخص بہت غریب ہے سہارا ہے، کوئی کما سن والا نہیں ہے
کوئی اولاد نہیں صرف دو لڑکیاں ہیں۔ اور ابھی طبیعت بہت علیل ہے
ان کے پارٹ کا آرگنیشن ہے براہ کرم اپنی اپنے زکوٰۃ خاؤنڈیشن سے
اس غریب کی زیادہ سے زیادہ امداد کریں اور علیہ السلام ماجور ہوں

MAULANA MD. TABREZ ALAM BARKATI
JAMIA FAIZAANE AALA HAZRAT TRUST
KAUSA, MUMBRA,



(Signature)

23/4/2026

9324291944